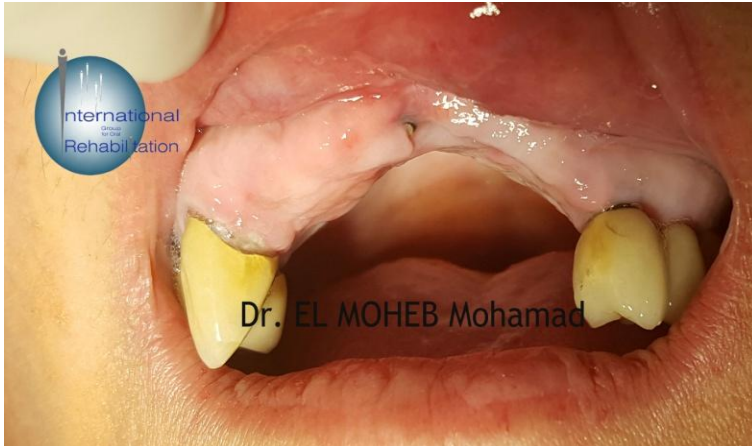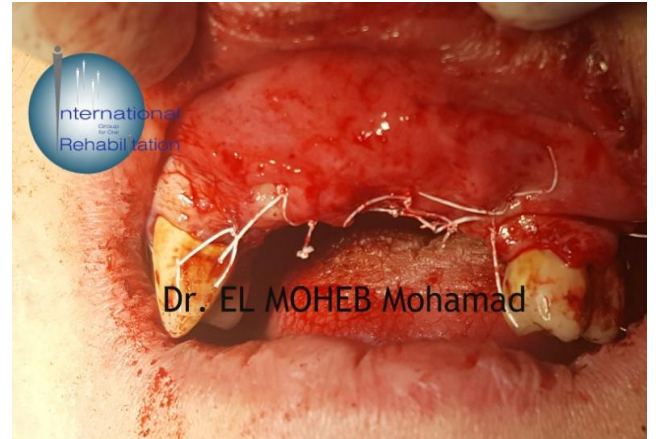


Clinical case presentation:

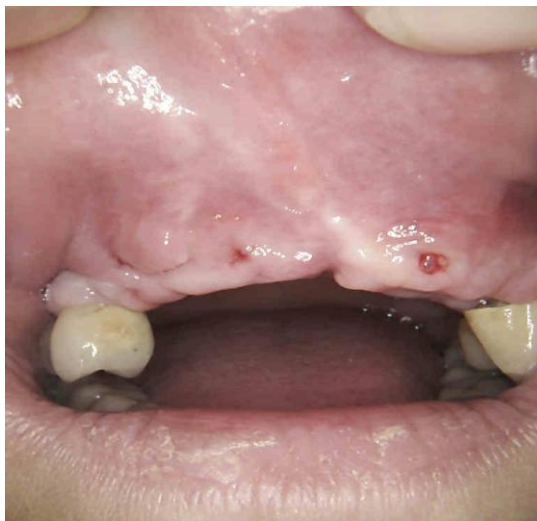- A female patient having 4 implants presented with severe vertical bone resorption.
- Treatment plan formed by Dr. El Moheb:
 1. Extraction of the implants.
 2. Vertical bone augmentation using MPM bone graft, PTFE membrane and PTFE sutures.



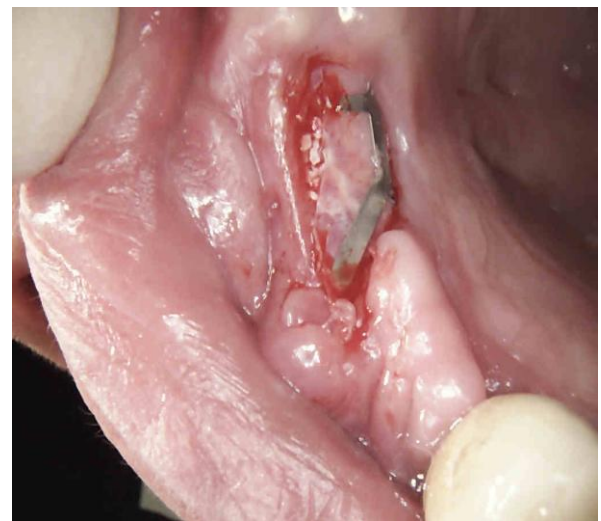Initial situation



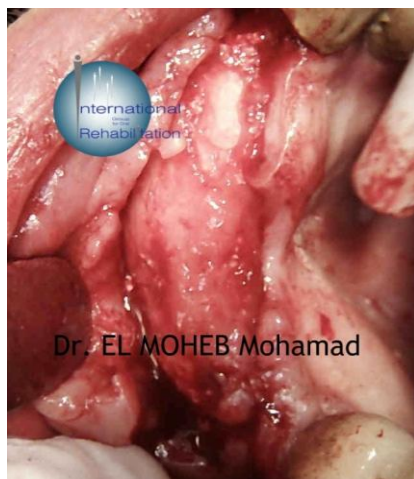Picture captured after the surgical operation – Dr. El Moheb used MEDIPAC PTFE sutures for this purpose



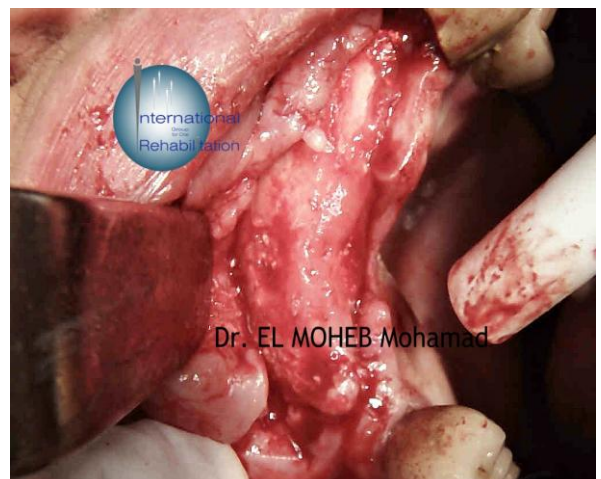6 months later



Membrane exposure, yet no implication (2 months after exposure)



6 months later



6 months later