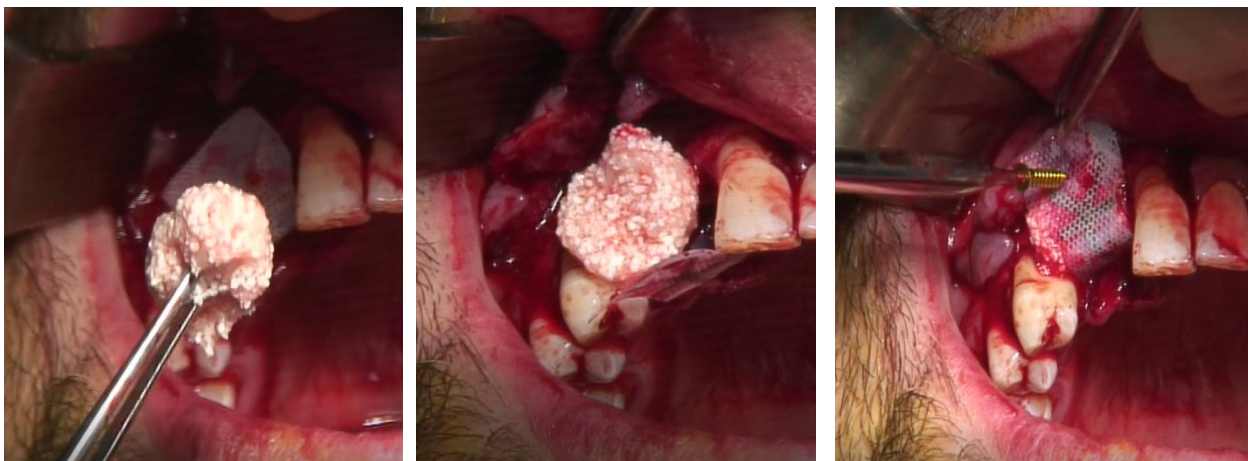
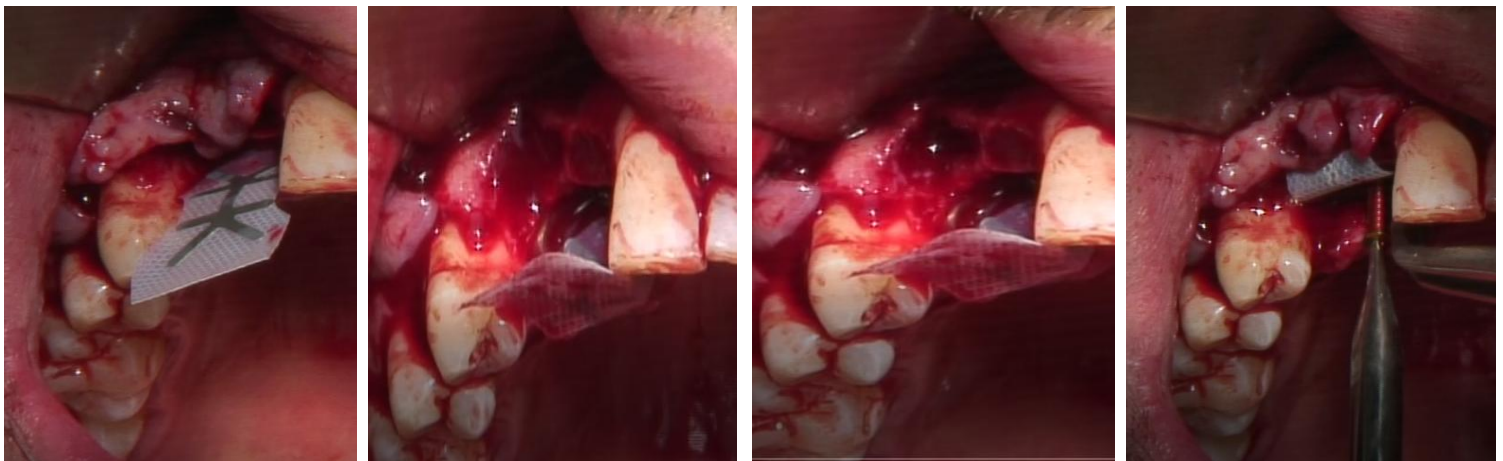
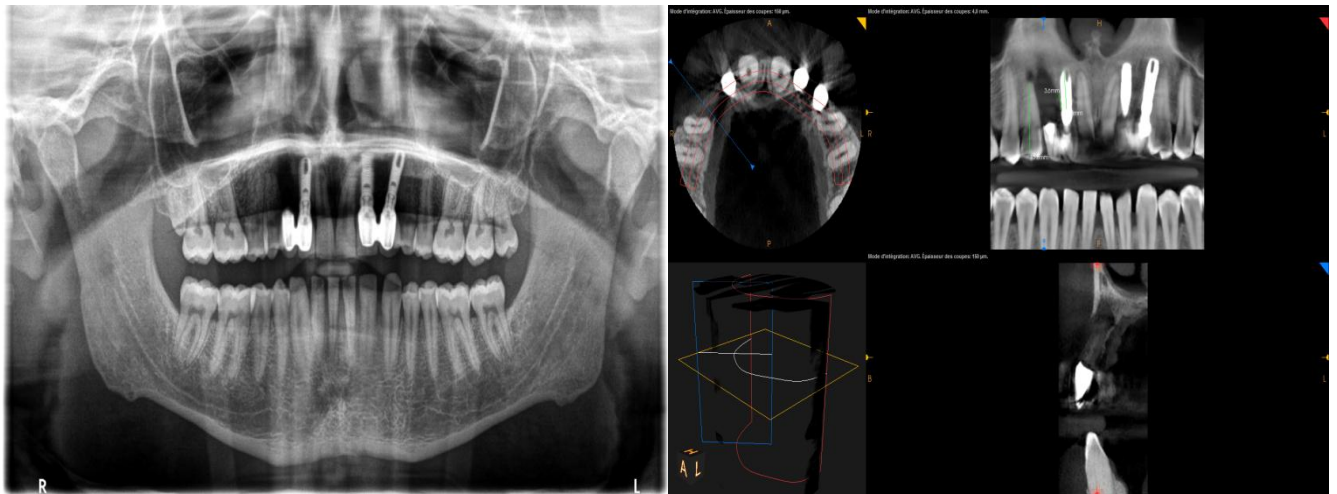
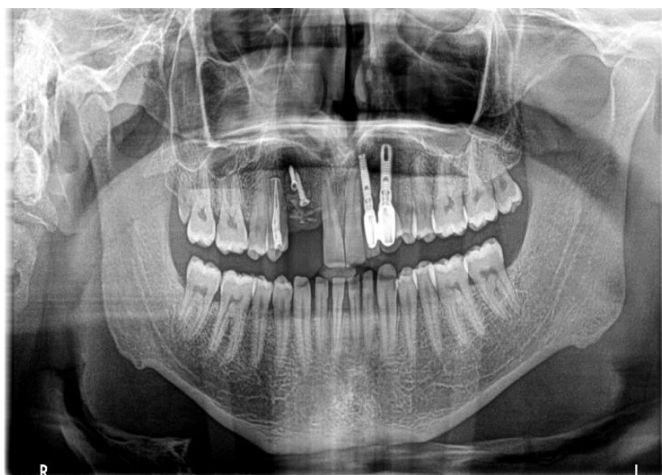


Clinical case presentation:

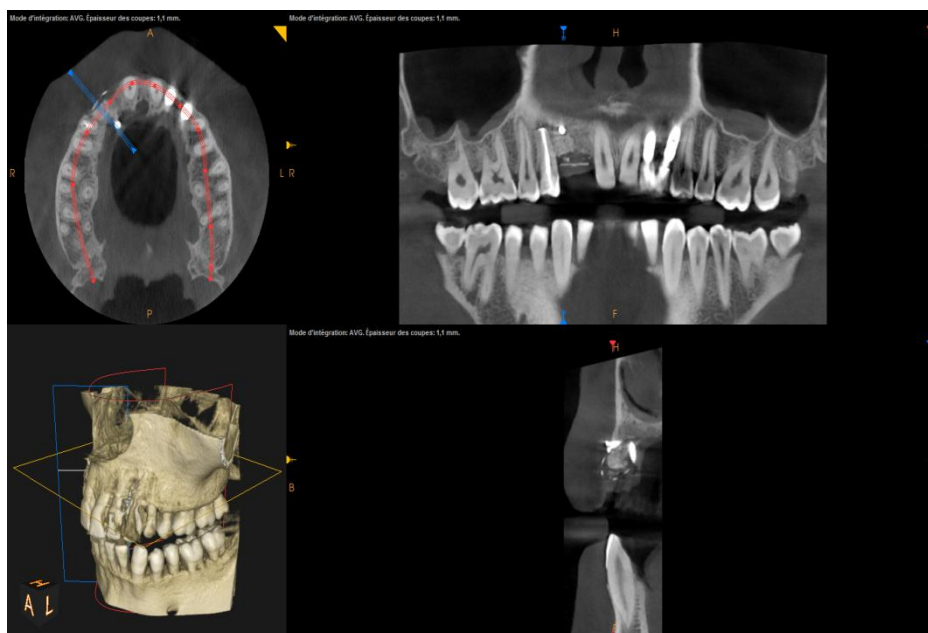
- A male patient was scheduled to have 2 implants replaced, particularly in the lateral incisor's and the canine's positions.
- The canine implant integrity was proved to have failed and his former dental surgeon removed the implant component toward finding a solution.
- Then, the patient visited Dr. Mohamad El Moheb's dental clinic where it was found that the premolar's situation was the reason for the above incident. Dr. El Moheb decided to treat the premolar and deduct wholly the left implant. For the Vertical Bone Augmentation, he utilized MPM (Mineralized Plasmatic Matrix) bone grafting and PTFE membrane accompanied by PTFE sutures. 6 months later, the new implants were successfully placed.





Exactly after bone graft placement

6 months later



Vertical bone augmentation

Drilling for implant placement

Implant placement

